

# Practical Guidelines for the Treatment of AMD

## Clinical Advisory Committee



CHAIR OF COMMITTEE

**Jeffrey Gerson, OD, FFAO**  
Grin Eye Care  
Olathe, KS



**Glenn Corbin, OD**  
Wyomissing Optometric Center  
Wyomissing, PA



**Steve Ferrucci, OD, FFAO**  
Sepulveda VA Hospital  
Sepulveda, CA



**Paul M. Karpecki, OD, FFAO**  
Kentucky Eye Institute  
Lexington, KY



**Gary Kirman, OD**  
Kirman Eye  
Hummelstown, PA



**Kim Reed, OD, FFAO**  
Ophthalmic Industry Consultant,  
Member of the State of Florida  
Governor's Task Force on Diabetes



**Laurie Sorrenson, OD, FFAO**  
Lakeline Vision Source  
Cedar Park, TX

*Over the past 15 years*, tremendous advances have been made in the detection and treatment of age-related macular degeneration (AMD). Numerous peer-reviewed scientific papers are published every month, covering a broad range of topics ranging from epidemiology to treatment. Although the expanded knowledge is welcome news, the information overload has made it difficult for clinicians to keep up with the science, much less understand the implications for patient care. To address this need, MacuLogix assembled a clinical advisory board that includes leading educators and private practice clinicians with large AMD practices. The advisory board was charged with the task of developing practical, evidence-based guidelines that can be implemented in a medically-oriented practice.

The following recommendations represent a consensus opinion and are not exclusionary of different approaches. The goal here was to develop a treatment algorithm that would be beneficial to all patients and was broadly agreed upon by all clinicians because it is evidence-based.

A Supplement to

**REVIEW**  
OF OPTOMETRY

## Goal of AMD Management

The goal of managing AMD is to preserve visual function, including but not limited to visual acuity. To achieve this goal, proper early detection, diagnosis, monitoring, and treatment must be practiced. Currently, doctors are too passive when diagnosing and treating nonexudative AMD.<sup>1-3</sup> Nonexudative AMD is often not diagnosed until the patient presents with drusen and visual acuity loss. By this criterion, the patient likely has had the disease for years. The patient has lost some of the potential benefits of treatment. The patient is at higher risk of central visual loss, especially in the first eye that progresses to choroidal neovascularization (CNV).<sup>4,5</sup> Because there is no cure for AMD, the goal is to halt or slow the disease progression. Earlier detection allows earlier treatment, which leads to better patient outcomes. With proper care, significant visual acuity loss may be prevented in many patients.

## The Importance of Visual Function in Nonexudative AMD Diagnosis

AMD is often missed upon routine clinical examination. A recent study found that 25% of patients referred to a clinical study had normal retinal health, in fact, had clinically evident AMD based upon fundus photography that was not identified by the primary care provider.<sup>6</sup> As previously mentioned, many

---

***Earlier detection allows earlier treatment, which leads to better patient outcomes. With proper care, significant visual acuity loss may be prevented in many patients.***

---

doctors will not diagnose nonexudative AMD until there is visual acuity loss. Drusen may be found and documented on clinical examination, but the diagnosis of AMD is often not made.

*Why is there the hesitation to diagnose AMD?* One cause of indecision stems from the understanding that not all drusen are caused by AMD, while others are based on assumptions about what the patient will do



## DID YOU KNOW

**Up to 78% of AMD patients have substantial, irreversible vision loss at first treatment, including 37% who are legally blind in at least one eye.<sup>1,2</sup>**

after the diagnosis is made. For example, if a patient is told that she has AMD but she has no symptoms, will the patient be compliant with care? Perhaps she won't. However, we can easily assume that if a patient is not told that she has AMD, then she surely will not make changes or take steps to be compliant with her care. We have witnessed a similar challenge in the management of glaucoma, because the patients do not generally experience symptoms such as visual function loss until very late in the disease.

Most doctors find that when they can point to a symptom of disease, patients are more motivated to be compliant. Consider the following examples.

1. "Mrs. Smith, you have age-related macular degeneration. Fortunately, it is not affecting your vision. My treatment plan is..."
2. "Mrs. Smith, the reason that you are having difficulty reading is because you have age-related macular degeneration. My treatment plan is..."

The second option is superior and will more likely result in better patient compliance. The measurement of dark adaptation speed can further address these issues. Dark adaptation impairment has been found to

be highly sensitive and specific for the detection of AMD. The accuracy of using impaired dark adaptation to identify AMD is 90%.<sup>7</sup> Thus, dark adaptation can be used as part of the differential diagnosis to understand whether the

drusen noted are likely caused by AMD.

This characteristic dark adaptation impairment occurs very early in the disease process. Dark adaptation impairment can be present up to three years before the disease can be detected by clinical examination or retinal imaging.<sup>8</sup> This provides the clinician the opportunity to treat the disease earlier and increase the probability of halting or slowing the progression

of the disease. Because the patient's dark adaptation is abnormal, the frequent complaint of difficulty with night vision may be used to enhance compliance to care. For example:

*for you is..."*

Patients with AMD express difficulty with their night vision and specifically driving at night.<sup>9,10</sup> Patients understand that they have a functional deficit or symptom caused by AMD and are eager to save their central vision.

---

***Subclinical AMD was identified by histopathological and clinical research, which found that AMD has structural and functional consequences before drusen are clinically evident.***

---

3. *"Mrs. Smith, the reason that you have difficulty driving at night is because you have age-related macular degeneration. Our goal now is to prevent central vision loss or other visual function deficits. My treatment plan*

identified, named subclinical AMD. Subclinical AMD was identified by histopathological and clinical research, which found that AMD has structural and functional consequences before drusen are clinically

**Subclinical AMD**

A new stage of AMD has been

**Peer-Reviewed Study Shows AMD is Frequently Overlooked**

A recent study published in *JAMA Ophthalmology* reveals how frequently optometrists and ophthalmologists fail to diagnose age-related macular degeneration (AMD).<sup>1</sup> The cross-sectional study, which included 1,288 eyes (644 adults) from patients enrolled in the Alabama Study on Early Age-Related Macular Degeneration (ALSTAR),<sup>2,3</sup> revealed that doctors are missing AMD about 25% of the time. Also quite concerning is that 30% of the undiagnosed eyes in the study had large drusen, a known risk factor for wet AMD.<sup>1</sup>

The authors set out to determine to what extent AMD is under-diagnosed by primary eye care physicians when the disease is actually present. In the study, they reviewed the medical records of 644 adults 60 years or older who were enrolled in ALSTAR. To be eligible, the person's medical record from the most recent comprehensive dilated examination did not indicate a diagnosis of AMD in either eye, and the medical record notes did not contain terms that signified the signs of AMD.

Each patient in the ALSTAR study had digital color fundus photos taken, which were reviewed by masked, trained graders who determined the presence or absence of AMD findings according to the Clinical Age-Related Maculopathy Staging (CARMS) system.<sup>4</sup> The types of AMD-associated lesions also were noted.

The results revealed that one of four eyes studied was not diagnosed with AMD during the dilated fundus examination, despite these eyes having macular characteristics indicative of AMD in the fundus photos. Approximately three-fourths of the 320 undiagnosed eyes had 10 or more small drusen (249 [77.8%]) and/or intermediate drusen (250 [78.1%]), and 96 (30.0%) of the undiagnosed eyes had large drusen.

Although the study authors say reasons for the missed diagnoses remain unclear, they point out that improved AMD detection strategies may be needed in primary eye care since many of these patients would have been candidates for therapeutic intervention with nutritional supplements.

1. Neely DC, Bray KJ, Huisinigh CE, Clark ME, McGwin G, Owsley C. Prevalence of undiagnosed age-related macular degeneration in primary eye care. *JAMA Ophthalmol.* 2017;135(6):570-5.

2. Owsley C, Huisinigh C, Jackson GR, et al. Associations between abnormal rod-mediated dark adaptation and health and functioning in older adults with normal macular health. *Invest Ophthalmol Vis Sci.* 2014;55(8):4776-89.

3. Owsley C, Huisinigh C, Clark ME, Jackson GR, McGwin G Jr. Comparison of visual function in older eyes in the earliest stages of age-related macular degeneration to those in normal macular health. *Curr Eye Res.* 2016;41(2):266-72.

4. Seddon JM, Sharma S, Adelman RA. Evaluation of the clinical age-related maculopathy staging system. *Ophthalmology.* 2006;113(2):260-6.

evident. Histopathological studies have shown that the retinal pigment epithelium (RPE) cells deposit locally generated cholesterol beneath the RPE cell layer and in Bruch's membrane before drusen are formed.<sup>11</sup> These lesions were first identified in donor eyes using an electron microscope.

With disease progression, cholesterol continues to accumulate, resulting in focal areas that are sufficiently thickened to be identified as drusen. Thus, drusen caused by AMD are the tip of an iceberg of the earliest lesions caused by AMD. More dysfunction is present than would be concluded simply on the appearance of drusen.

This cholesterol accumulation causes three primary insults to the retina—inflammation, oxidative stress, and disruption of oxygen and nutrition supplied to the outer retina. One functional aspect of the role of nutrients in AMD that has been proven to be disrupted is vitamin A transport.<sup>10</sup> Vitamin A is critical for rod-mediated dark adaptation. Disruption of vitamin A availability dramatically slows dark adaptation. Increased disease severity is correlated with increased dark adaptation impairment.<sup>12,13</sup> It has been shown that the dark adaptation impairment can be detected before AMD is clinically evident.<sup>8</sup> If histopathology

---

***Impaired dark adaptation is the first detectable consequence of AMD and can be used to identify patients with subclinical disease.***

---

were to be performed on a patient over the age of 50 years with no other comorbid diseases and impaired dark adaptation, subclinical lesions associated with AMD would likely be found. Thus, dark adaptation is a functional marker of subclinical AMD.

Improved understanding of the histopathology of the disease, combined with a thorough understanding of its functional consequences provide several clinically useful observations. First, AMD manifests itself before drusen are visible through impaired dark adaptation, which is expressed by the patient as night



## DID YOU KNOW

**Unlike macular pigment optical density (MPOD) testing or genetic tests, the AdaptDx does not measure AMD risk. This easy-to-perform test is diagnostic of AMD, indicating that disease is already present.**

vision difficulties. Thus, impaired dark adaptation is the first detectable consequence of AMD and can be used to identify patients with subclinical disease. Patients with impaired dark adaptation and small drusen have AMD because the appearance of any drusen is a consequence of previously undetectable lesions revealing themselves. Dark adaptation can be used to evaluate whether small drusen are focal deposits or the visible tips of the lesions caused by AMD. Evaluating structure and function together provides the clinician with improved diagnostic accuracy and the opportunity to treat the disease earlier than by use of structure alone.

## Nonexudative AMD Diagnosis and Staging

The gold standard for the diagnosis and staging of nonexudative AMD is the use of a grading system developed for epidemiological studies and clinical trials. These grading systems rely on careful inspection of three-field stereo-fundus photographs to grade the presence of drusen and/or pigmented changes. For a variety of reasons, these systems have not been widely adopted in primary eye care. A thorough understanding of AMD pathogenesis suggests that diagnosing and staging AMD should rely on both structure and function. Thus, the Practical Guidelines use structure and function to assist with AMD diagnosis and staging.

The Beckman Initiative for Macular Research published a classification system designed for use in a primary care setting.<sup>14</sup> The Practical Guidelines presented here are a modification of the Beckman system. The Beckman system is based solely upon structural findings; whereas the Practical Guidelines are based upon the structural findings and augmented by func-

tional findings such as the dark adaptation status. The Practical Guidelines differ from the Beckman system in the following ways: **(1)** The system defines a disease stage named subclinical AMD, which is the stage at which abnormal dark adaptation is present in the absence of drusen and/or RPE pigmentary changes; **(2)** the definition of early AMD is expanded. The Beckman system requires medium drusen for a diagnosis

---

***Based upon our current understanding of AMD pathogenesis, the stages of subclinical, early, and intermediate AMD all represent different clinical manifestations of the same underlying disease process. Thus, the treatment of the disease should be initiated at first detection, regardless of the stage.***

---

of AMD; whereas, the Practical Guidelines include small drusen when the dark adaptation impairment is present. In addition, the Practical Guidelines include RPE pigmentary abnormalities in the presence of dark adaptation impairment, whereas the Beckman system does not consider pigmentary abnormalities for the definition of early AMD. The two systems have identical definitions for intermediate and advanced AMD.

## Treatment

Currently, there is no cure for AMD. Anti-VEGF therapy used for the treatment of CNV may not be durable over the long term for some patients. Patients on long-term anti-VEGF therapy have an elevated risk of vision loss caused by progression to GA.<sup>15</sup> Thus, the management of AMD has two primary goals, both aimed at preserving vision: **(1)** Prevent progression to advanced AMD (GA or CNV), and **(2)** effectively detect and manage CNV. Achieving these goals will allow the patient to enjoy additional years of high-quality central vision, enhancing the odds of a better quality of life. With increased life expectancy and earlier age of AMD disease onset, it is reasonable that a patient may have the disease for 10, 20, or 30 years after initial diagnosis. Early diagnosis and consistent, aggressive management of the disease is required to

minimize risk of vision loss.

Much of AMD treatment is based on modifying risk factors, such as smoking, diet, light exposure and other lifestyle contributors. There are, however, non-modifiable risk factors that still should be considered—namely genetics. Although we can't do anything to alter a patient's genetics currently, we need to realize that, moving forward, outcomes are largely influenced by genes. At the very least, knowing a person's family history can help influence the treatment course. For example, knowing a family member had a poor outcome may help motivate a patient to more closely follow recommendations.

Based upon our current understanding of AMD pathogenesis, the stages of subclinical, early, and intermediate AMD all represent different clinical manifestations of the same underlying disease process. Thus, the treatment of the disease should be initiated at first detection, regardless of the stage. The following treatment recommendations apply to patients with all five stages of AMD.

## Treatment Recommendations for all Five Stages of AMD

- » Prescribe smoking cessation programs
- » Prescribe nutritional supplementation
- » Discuss lifestyle modifications with respect to diet and exercise
- » Systemic disease management
- » Prescribe blue light protection
- » Prescribe UVA and UVB sunglasses protection for outdoors

## Smoking Cessation

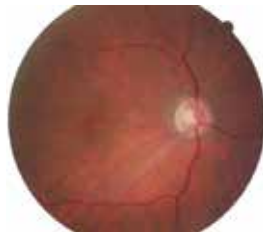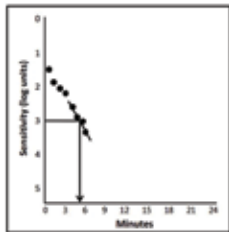
Smoking is the largest modifiable risk factor for the progression of both CNV and GA.<sup>16</sup> Current smokers carry a 2.5 to 4.8 times higher risk than non-smokers for late AMD.<sup>17</sup> Former smokers show less risk of development of late AMD than current smokers, in a dose-dependent relationship. Although this risk has

## AMD Classification

<b>Normal</b>	<input type="checkbox"/> Absence of drusen <input type="checkbox"/> Absence of RPE pigmentary abnormalities <input type="checkbox"/> Normal dark adaptation
<b>Subclinical AMD</b>	<input type="checkbox"/> Absence of drusen <input type="checkbox"/> Absence of RPE pigmentary abnormalities <input type="checkbox"/> Abnormal dark adaptation
<b>Early AMD</b>	<input type="checkbox"/> Absence of drusen <input type="checkbox"/> Presence of RPE pigmentary abnormalities <input type="checkbox"/> Abnormal dark adaptation <b>OR</b> <input type="checkbox"/> Presence of small or medium drusen <input type="checkbox"/> Absence of RPE pigmentary abnormalities <input type="checkbox"/> Abnormal dark adaptation <b>OR</b> <input type="checkbox"/> Presence of medium drusen <input type="checkbox"/> Absence of RPE pigmentary abnormalities
<b>Intermediate AMD</b>	<input type="checkbox"/> Presence of medium drusen <input type="checkbox"/> Presence of RPE pigmentary abnormalities <b>OR</b> <input type="checkbox"/> Presence of large drusen
<b>Advanced AMD</b>	<input type="checkbox"/> Presence of choroidal neovascularization (CNV) <b>OR</b> <input type="checkbox"/> Presence of geographic atrophy (GA)

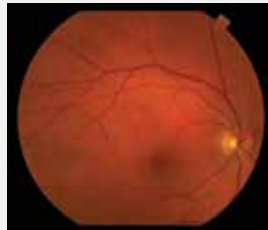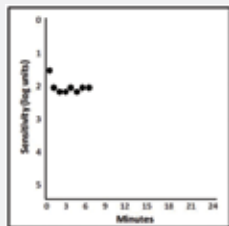
**NOTES:**

**Retinal area to be examined:** The area to be examined is roughly within a two-disk diameter radius around the fovea.



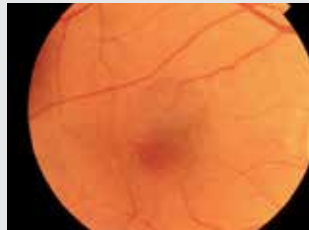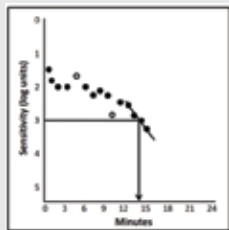
This patient exhibits normal dark adaptation (L), and a healthy macula (R).

*Image: Amanda S. Legge, OD*



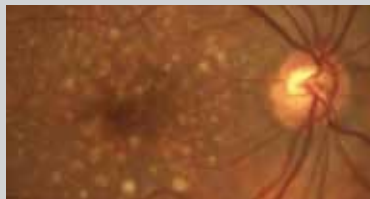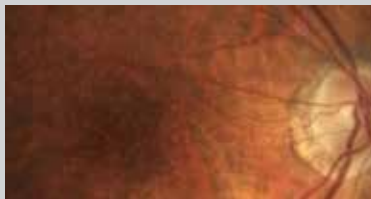At the subclinical stage, patients demonstrate abnormal dark adaptation (L), but still exhibit no evidence of drusen formation or retinal pigment epithelial defects via fundus evaluation (R).

*Image: Steven Ferrucci, OD*



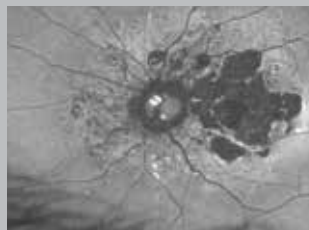
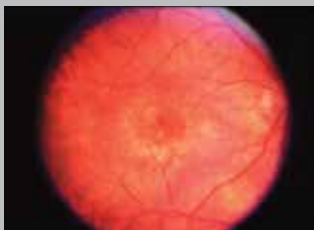Early AMD associated with significantly abnormal dark adaptation (L) and small drusen formation (R).

*Image: Paul M. Karpecki, OD*



Patients with intermediate AMD typically present with medium-sized (L) or large (R) drusen formation.

*Image: Mohammad Rafeetary, OD*



Two hallmark manifestations of advanced AMD include choroidal neovascularization (L) or severe geographic atrophy (R), as seen on fundus autofluorescence.

*Images: Mark T. Dunbar, OD (L), Amanda S. Legge, OD (R)*

**NOTES:**

**DRUSEN SIZE:** Small drusen are less than 63 microns in diameter. Large drusen are 125 microns or greater in diameter. Medium drusen fall in between. One-hundred twenty-five microns is roughly equal to the width of the central retinal vein crossing the optic disk. Thus, large drusen diameter is equal to or greater than the width of the vein. Small drusen diameter is roughly a quarter the width of the vein or smaller.

been demonstrated in multiple studies worldwide, smoking cessation has not been widely emphasized by primary eye care providers. In one study, 90% of patients with AMD were not advised to stop smoking.<sup>18</sup> Fewer than half of smokers know that smoking may contribute to blindness even though this fact is an effective motivator for smoking cessation.<sup>19</sup> Encouraging smoking cessation is the best method to reduce risk of central vision loss.

### Nutritional Supplementation

No topic in the management and prevention of nonexudative AMD causes more controversy than nutritional supplementation strategies. Evidence strongly suggests that patients should be prescribed nutritional supplements because, on average, treated patients have better outcomes than untreated patients.<sup>20-22</sup> The reasons for improved outcomes include both the beneficial effects of the supplements themselves as well as increased compliance with care. Based on the clinical experience of the authors, a patient who is prescribed therapeutic intervention is more likely to be compliant with their follow-up monitoring visits than a patient who is not prescribed treatment. More frequent visits provide the eye care provider with more

---

### ***The Practical Guidelines recommend nutritional supplementation for all stages of AMD.***

---

opportunities for early detection of progression—e.g., development of CNV—and prompt intervention when indicated. The Practical Guidelines treatment protocol is designed to reduce the risk of progression of the disease, but periodic clinical examination is essential to allow detection of treatable CNV.

The Practical Guidelines recommend nutritional supplementation for all stages of AMD. There are three primary options for the selection of an appropriate nutritional supplement. The first option is to prescribe a macular pigment supplement (the xanthophylls: lutein, zeaxanthin, meso-zeaxanthin). The second option is to prescribe a supplement containing

both xanthophylls and antioxidants, including zinc and vitamins E and C (e.g., an AREDS2 supplement). The third option is to prescribe a xanthophyll supplement to patients with subclinical and early AMD, and a xanthophyll-antioxidant combination supplement to patients with intermediate AMD or patients that progress to intermediate AMD. The relative merits of each option are debatable, and knowledge continues to expand about the many factors that contribute to AMD progression. However, it is reasonable to conclude that it is better to prescribe a supplement than not prescribe a supplement.

### Lifestyle Modifications With Respect to Diet & Exercise

Following a healthy diet, exercising regularly and maintaining overall health are sound goals for all patients.<sup>22</sup> These lifestyle choices may act synergistically to prevent or delay onset or progression of AMD. One study found that women who followed a healthy diet, engaged in physical exercise, and avoided smoking had substantially lower risk of early AMD compared with women who did not follow these healthy lifestyles.<sup>23</sup> Epidemiological evidence supports the following risk-reduction recommendations:

**Omega Fatty Acids:** Epidemiological studies have found substantial benefit from higher dietary intake of essential fatty acid-rich foods, especially DHA, found in many species of fish.<sup>24</sup> Doctors should recommend that

patients consume fish rich in DHA and/or supplement with high-quality, highly bioavailable omega fatty acid products.

**Mediterranean Diet:** This diet includes high intake of fruits, legumes, vegetables, nuts, seeds, and other grains; olive oil as the main source of monounsaturated fat; dairy products, fish, poultry, and wine in moderate amounts; and limited intake of red and processed meats. Studies suggest that subjects who regularly consume a Mediterranean-like diet carry an overall lower risk of development of advanced AMD as compared to those who regularly consume a traditionally Western diet.<sup>25</sup> A recommendation should



## The Road to Improved Outcomes

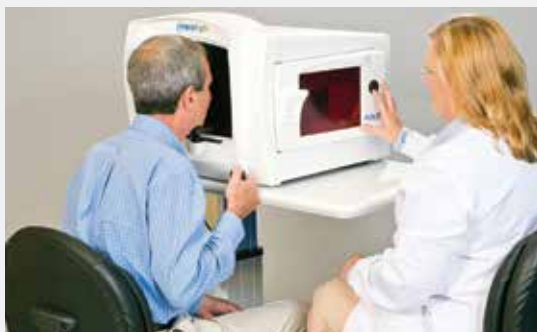Current technology may lead to a sense of complacency, and does not always enable us to detect AMD early enough. This is easily overcome when dark adaptation testing is available. While there is no cure for early AMD, it is important to diagnose the disease as early as possible to increase monitoring, educate patients and start measures that may slow progression.

We can recommend lifestyle changes, such as smoking cessation, exercise and a healthy diet including antioxidant vitamins and UV light protection with sunglasses, as a start. Indeed, doctors who have the tools needed for earlier detection have a tremendous opportunity to help their patients and advance their practices.

The challenge is that many cases of AMD are overlooked based on the absence of structural findings using some of the most advanced technology. For example, ocular coherence tomography (OCT) is essential for detecting and managing many retinal diseases, but it only looks at structure. Depending on interpretation, the OCT scan of a patient with a few small drusen is often normal and potentially underestimates the extent of disease. By the time photoreceptor ellipsoid layer thinning is visible on OCT, macular function may be significantly impaired.

Dark adaptation with the AdaptDx is a straightforward adjunct to OCT, fundus photography and standard clinical examination. This functional test allows you to detect early AMD up to three years before it becomes clinically evident.<sup>1</sup> Several peer-reviewed studies have shown that dark adaptation function is dramatically impaired from the earliest stages of AMD, with increasing impairment as the disease progresses.<sup>2,3</sup>

In a recently published study, subjects with impaired dark adaptation were twice as likely to develop clinically evident AMD and eight times as likely to advance beyond the earliest stage of AMD.<sup>4</sup> The only commercially available automated dark adaptometer, called the AdaptDx, measures a patient's Rod Intercept (RI) time. RI is the number of minutes it takes for the eye to adapt from bright light to darkness at a standard threshold stimulus level. The AdaptDx test provides a clear and objective measurement of retinal function with 90% sensitivity and specificity.<sup>5</sup> An RI of less than 6.5 minutes indicates normal dark adaptation consistent with healthy photoreceptor function. An RI greater than 6.5 minutes indicates impaired dark adaptation, most often due to AMD in patients over age 60, unless there is a pre-existing hereditary retinal degeneration or significant vitamin A deficiency, which is rare in the United States.



Testing dark adaptation function with the AdaptDx<sup>®</sup> can help diagnose AMD at least three years earlier than drusen are visible.

1. Owsley C, McGwin G, Clark M, et al. Delayed rod-mediated dark adaptation is a functional biomarker for incident early age-related macular degeneration. *Ophthalmology*, October 30, 2015.

2. Owsley C, Jackson GR, White MF, Feist R, Edwards D. Delays in rod-mediated dark adaptation in early age-related maculopathy. *Ophthalmology*. 2001;108, 1196-1202.

3. Curcio CA, Johnson M. Structure, function, and pathology of Bruch's membrane. In: Ryan SJ, et al, eds. *Retina*, Vol 1, Part 2: Basic Science and Translation to Therapy. 5th ed. London: Elsevier; 2013:466-81.

4. Owsley C, McGwin G, Clark ME, et al. Delayed rod-mediated dark adaptation is a functional biomarker for incident early age-related macular degeneration. *Ophthalmology*. 2016;123(2):344-51.

5. Jackson GR, Scott IU, Kim IK, Quillen DA, Iannaccone A, Edwards JG. Diagnostic sensitivity and specificity of dark adaptometry for detection of age-related macular degeneration. *Investigative Ophthalmology & Visual Science*. 2014;55(3):1427-31.

be made that patients avoid traditionally “Western” dietary pitfalls (high glycemic index foods, high-fat dairy products, fried foods, and processed meats), and instead, follow healthier eating styles like the Mediterranean diet.

**Exercise:** An active lifestyle has been shown to reduce the risk of progression to CNV.<sup>26–28</sup> For those who participated in cardiovascular exercise of any intensity three or more times per week, the incidence of CNV was reduced by 33 percent. For individuals who walked one or more blocks per day, the incidence of CNV was half compared with those who walked less than one block per day.<sup>27</sup> These levels of physical activity are achievable by almost all patients.

### Systemic Disease Management

Several systemic conditions carry an increased risk of the development of AMD, based on epidemiological studies. Cardiovascular disease, diabetes, hypocholesterolemia, and obesity have all been associated

---

### ***More frequent visits provide the clinician increased opportunity to detect CNV before visual acuity loss.***

---

with increased risk of AMD and/or progression of AMD.<sup>26,29–31</sup> Body mass index and abdominal obesity are independent risk factors for progression to advanced AMD.<sup>26</sup> Unquestionably, good clinical practice mandates management of systemic disease for all patients, which at a minimum includes screening and subsequent referral to appropriate health care professionals. Discussion with your patient regarding the connection between risk of vision loss and any comorbid systemic diseases may enhance adherence to prescribed care regimens.

### Retinal Light Protection

Epidemiological evidence suggests that chronic sunlight exposure increases the risk of incident AMD and its progression.<sup>32</sup> Randomized clinical trials are impractical to evaluate the efficacy of protective lenses. High energy visible light (HEVL) blocking (sometimes

referred to as blue-light blocking) intraocular lenses have been widely implanted for over a decade even though the protective properties of these lenses have not been systematically evaluated. One interesting observational study found reduced progression of GA in patients who had blue-blocking intraocular lenses implanted.<sup>33</sup> Likewise, there may be a potential benefit of protective eyewear. Protective eyewear has a couple of advantages over blue-blocking intraocular lenses. First, the amount of tint can be made task appropriate (e.g., a darker tint for driving), and second, eyewear is removable should the patient choose to discontinue use. Prescribe full-spectrum UV protection for patients and consider HEVL-blocking eyeglass lenses, which are becoming more widely available and affordable.

### Monitoring

For a patient with AMD, more frequent retinal examinations are recommended. Moving from a 12-month follow-up interval to a six-month follow-up interval may be useful for monitoring disease progression.<sup>34</sup> More frequent visits provide the clinician increased opportunity to detect CNV before visual acuity loss.

Often, home monitoring by Amsler grid is ineffective or the patient defers reporting symptoms between office visits. The follow-up visit interval may be shortened to every three or four months for patients who are progressing rapidly or are at high risk of CNV.

### Concluding Remarks

These recommendations form a solid foundation for caring for patients with AMD. These practical guidelines also may be augmented in practices where personalized medicine or more complex approaches to supplementation are routinely employed. However, the advisory board concluded that such methods are still being researched in clinics and require more evidence before a consensus opinion can be reached.

The guidelines will be periodically reviewed and updated as warranted by new evidence that clarifies best practices for the treatment of nonexudative AMD. •

## Resources

- Olsen TW, Feng X, Kasper TJ, Rath PP, Steuer ER. Fluorescein angiographic lesion type frequency in neovascular age-related macular degeneration. *Ophthalmology*. 2004;111(2):250-255. doi:10.1016/j.ophtha.2003.05.030.
- Cervantes-Castañeda RA, Banin E, Hemo I, Shpigel M, Averbukh E, Chowers I. Lack of benefit of early awareness to age-related macular degeneration. *Eye*. 2007;22(6):777-781. doi:10.1038/sj.eye.6702691.
- Chevreaud O, Semoun O, Blanco-Garavito R, et al. Visual acuity at presentation in the second eye versus first eye in patients with exudative age-related macular degeneration. *Eur J Ophthalmol*. 2016;26(1):44-47. doi:10.5301/ejo.5000649.
- Boyer DS, Antoszyk AN, Awh CC, et al. Subgroup analysis of the MARINA study of ranibizumab in neovascular age-related macular degeneration. *Ophthalmology*. 2007;114(2):246-252. doi:10.1016/j.ophtha.2006.10.045.
- Loewenstein A. The significance of early detection of age-related macular degeneration: Richard & Hinda Rosenthal Foundation lecture, The Macula Society 29th annual meeting. *Retina*. 2007;27(7):873-878.
- Neely DC, Bray KJ, Huisingsh CE, Clark ME, McGwin G, Owsley C. Prevalence of undiagnosed age-related macular degeneration in primary eye care. *JAMA Ophthalmol*. April 2017. doi:10.1001/jamaophthalmol.2017.0830.
- Jackson GR, Scott IU, Kim IK, Quillen DA, Iannaccone A, Edwards JG. Diagnostic sensitivity and specificity of dark adaptometry for detection of age-related macular degeneration. *Invest Ophthalmol Vis Sci*. 2014;55:1427-1431. doi:10.1167/iovs.13-13745.
- Owsley C, McGwin G, Clark ME, et al. Delayed rod-mediated dark adaptation is a functional biomarker for incident early age-related macular degeneration. *Ophthalmology*. 2016;123(2):344-351. doi:10.1016/j.ophtha.2015.09.041.
- Owsley C, McGwin G, Scilley K, Kallies K. Development of a questionnaire to assess vision problems under low luminance in age-related maculopathy. *Invest Ophthalmol Vis Sci*. 2006;47:528-535.
- Owsley C, McGwin G, Jackson GR, et al. Effect of short-term, high-dose retinol on dark adaptation in aging and early age-related maculopathy. *Invest Ophthalmol Vis Sci*. 2006;47:1310-1318.
- Pikuleva IA, Curcio CA. Cholesterol in the retina: the best is yet to come. *Prog Retin Eye Res*. 2014;41:64-89. doi:10.1016/j.preteyeres.2014.03.002.
- Owsley C, Jackson GR, White MF, Feist R, Edwards D. Delays in rod-mediated dark adaptation in early age-related maculopathy. *Ophthalmology*. 2001;108:1196-1202. doi:10.1007/s12177-008-9002-6.
- Jackson GR, Edwards JG. A short-duration dark adaptation protocol for assessment of age-related maculopathy. *J Ocul Biol Dis Infor*. 2008;1(1):7-11. doi:10.1007/s12177-008-9002-6.
- Ferris FL, Wilkinson CP, Bird A, et al. Clinical classification of age-related macular degeneration. *Ophthalmology*. 2013;120(4):844-851. doi:10.1016/j.ophtha.2012.10.036.
- Danis RP, Lavine JA, Domalpally A. Geographic atrophy in patients with advanced dry age-related macular degeneration: current challenges and future prospects. *Clin Ophthalmol Auckl NZ*. 2015;9:2159-2174. doi:10.2147/OPTH.S92359.
- Smith W, Assink J, Klein R, et al. Risk factors for age-related macular degeneration: Pooled findings from three continents. *Ophthalmology*. 2001;108(4):697-704.
- Chakravarthy U, Abugood C, Bentham GC, et al. Cigarette smoking and age-related macular degeneration in the EUREYE Study. *Ophthalmology*. 2007;114(6):1157-1163. doi:10.1016/j.ophtha.2006.09.022.
- Caban-Martinez AJ, Davila EP, Lam BL, et al. Age-related macular degeneration and smoking cessation advice by eye care providers: a pilot study. *Prev Chronic Dis*. 2011;8(6):A147.
- Handa S, Woo JH, Wagle AM, Htoon HM, Au Eong KG. Awareness of blindness and other smoking-related diseases and its impact on motivation for smoking cessation in eye patients. *Eye*. 2011;25(9):1170-1176. doi:10.1038/eye.2011.143.
- Hobbs RP, Bernstein PS. Nutrient supplementation for age-related macular degeneration, cataract, and dry eye. *J Ophthalmic Vis Res*. 2014;9(4):487-493. doi:10.4103/2008-322X.150829.
- Liu R, Wang T, Zhang B, et al. Lutein and zeaxanthin supplementation and association with visual function in age-related macular degeneration. *Invest Ophthalmol Vis Sci*. 2015;56(1):252-258. doi:10.1167/iovs.14-15553.
- Carneiro Â, Andrade JP. Nutritional and lifestyle interventions for age-related macular degeneration: a review. *Oxid Med Cell Longev*. 2017;2017:1-13. doi:10.1155/2017/6469138.
- Mares JA. Healthy lifestyles related to subsequent prevalence of age-related macular degeneration. *Arch Ophthalmol*. 2011;129(4):470. doi:10.1001/archophthalmol.2010.314.
- Querques G, Souied EH. The role of omega-3 and micronutrients in age-related macular degeneration. *Surv Ophthalmol*. 2014;59(5):532-539. doi:10.1016/j.survophthal.2014.01.001.
- Merle BMJ, Silver RE, Rosner B, Seddon JM. Adherence to a Mediterranean diet, genetic susceptibility, and progression to advanced macular degeneration: a prospective cohort study. *Am J Clin Nutr*. 2015;102(5):1196-1206. doi:10.3945/ajcn.115.111047.
- Seddon JM, Cote J, Davis N, Rosner B. Progression of age-related macular degeneration: association with body mass index, waist circumference, and waist-hip ratio. *Arch Ophthalmol*. 2003;121:785-792.
- Knudtson MD, Klein R, Klein BEK. Physical activity and the 15-year cumulative incidence of age-related macular degeneration: the Beaver Dam Eye Study. *Br J Ophthalmol*. 2006;90(12):1461-1463. doi:10.1136/bjo.2006.103796.
- Williams PT. Prospective study of incident age-related macular degeneration in relation to vigorous physical activity during a 7-year follow-up. *Invest Ophthalmol Vis Sci*. 2009;50(1):101. doi:10.1167/iovs.08-2165.
- Tan JSL, Mitchell P, Smith W, Wang JJ. Cardiovascular risk factors and the long-term incidence of age-related macular degeneration. *Ophthalmology*. 2007;114(6):1143-1150. doi:10.1016/j.ophtha.2006.09.033.
- Sun JK, Aiello LP, Stockman M, et al. Effects of dilation on electronic-ETDRS visual acuity in diabetic patients. *Invest Ophthalmol Vis Sci*. 2009;50:1580-1584. doi:10.1167/iovs.08-2426.
- Choudhury F, Varma R, McKean-Cowdin R, Klein R, Azen SP. Risk Factors for four-year incidence and progression of age-related macular degeneration: The Los Angeles Latino Eye Study. *Am J Ophthalmol*. 2011;152(3):385-395. doi:10.1016/j.ajo.2011.02.025.
- Sui G-Y, Liu G-C, Liu G-Y, et al. Is sunlight exposure a risk factor for age-related macular degeneration? A systematic review and meta-analysis. *Br J Ophthalmol*. 2013;97(4):389-394. doi:10.1136/bjophthalmol-2012-302281.
- Pipis A, Toulou E, Pillunat LE, Augustin AJ. Effect of the blue filter intraocular lens on the progression of geographic atrophy. *Eur J Ophthalmol*. September 2014:0. doi:10.5301/ejo.5000520.
- American Academy of Ophthalmology Retina/Vitreous Panel. Preferred Practice Pattern® Guidelines. Age-Related Macular Degeneration. 2015. Available at: www.aaopt.org/ppp.

Sponsored by



For more information, visit [maculogix.com](http://maculogix.com).